

DR. PUNAM CHATTERJEE
Ultrasonologist
MD (Radiodiagnosis)
Mobile: +91 9560968237, 7428 98854



B-13, Shivalik, Main Road, Near Malviya Nagar, New Delhi-110017
Tel: 011 2669 2948 / 2669 3435 Email: drchatterjee.radiology@gmail.com

Facilities available: Lab • X-ray • ECG • ECHO • TMT • PFT • 3D/4D Ultrasound • Colour Doppler

Patient's Name: SALMA

Age/Sex: 32Y/F

Ref. By: DR UPASANA GUPTA

22-03-2014

ULTRASOUND LOWER ABDOMEN/PELVIS-TVS

UTERUS is normal in size (65X42X40mm) with normal shape.

Endometrial echo is central and regular measuring approx. (7mm) in thickness. No collection seen in the endometrial canal. 8.5 mm hypoechoic intramural fibroid of posterior wall seen.

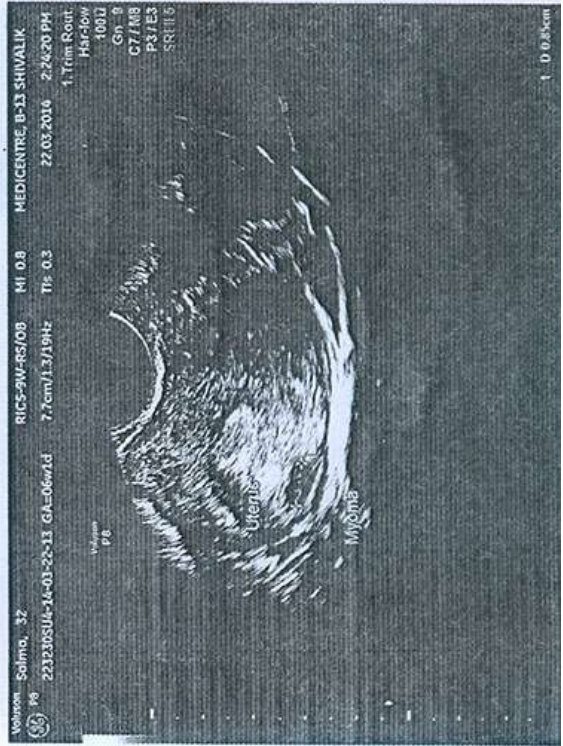
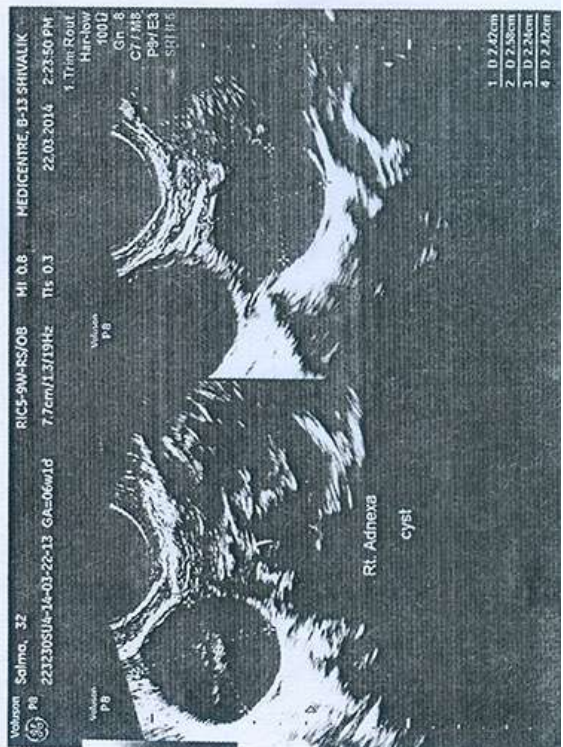
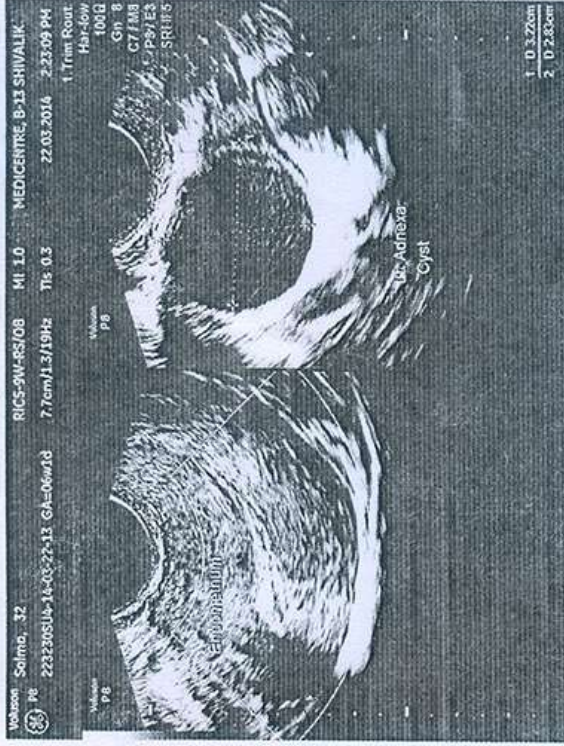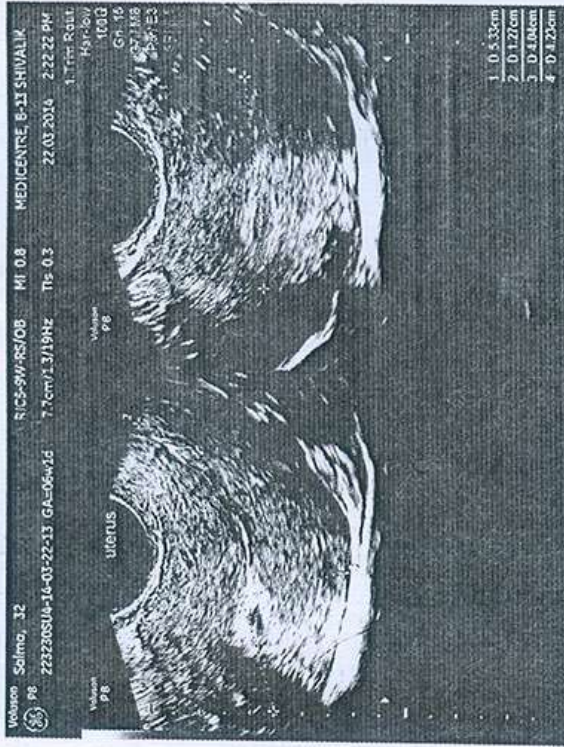32X28 mm well defined cyst with low lying fine internal echoes seen in left adnexa without appreciable wall vascularity. two well defined cystic lesions measuring 25x24 mm and 24x22 mm noted in right adnexa with internal fine echoes and irregular septae. Bilaterally normal ovarian tissue could not be made out –suggesting likely bilateral complicated? hemorrhagic ovarian cysts.

No free fluid seen in cul-de-sac.

ULTRASOUND PELVIS REVEALS NO significant ABNORMALITY.

ADVISED: Clinical correlation.

- The result pertains to the specimen submitted to the laboratory.
- The courts/forums at Delhi shall have exclusive jurisdiction in all disputes / claim concerning this test and /or results.
- If the results are alarming or unexpected, the patient is advised to contact the laboratory immediately for possible advice.
- Not for medico-legal purpose. Opinions based on material made available.



DR. PUNAM CHATTERJEE
Ultrasonologist
MD (Radiodiagnosis)
Mobile: +91 9560968237, 7428698854



B-13, Shivalik, Main Road, Near Malviya Nagar, New Delhi-110017
Tel.: 011 2669 2948 / 2669 3435 Email: drchatterjee.radiology@gmail.com

Facilities available: Lab • X-ray • ECG • ECHO • TMT • PFT • 3D/4D Ultrasound • Colour Doppler

Patient's Name: SALMA

Age/Sex: 34 Y/F

Ref. By. DR UPASANA GUPTA

11-07-2014

ULTRASOUND PELVIS(TVS)

UTERUS is normal in size (71X48X34mm) with normal shape and echopattern.

Endometrial echo is central irregular and poorly defined measuring approx. (6.5mm) in thickness. No collection/abnormal vascularity seen in the endometrial canal. No myometrial mass is seen.

Both ovaries appear normal in size and shows small clear follicles within .

Size: right ovary: 23x18x14mm (vol.3.1cc)

Left ovary : 22x15x11mm (vol.2.1cc)

Both adenexa are clear. No adenexal mass is seen in either side.

No free fluid seen in cul-de-sac.

OPINION:

ULTRASOUND PELVIS REVEALS NO SIGNIFICANT ABNORMALITY.

Resolution of complicated bilateral ovarian cystic lesions seen.

ADVISED: Clinical correlation.

- The result pertain to the specimen submitted to the laboratory.
- The courts/forums at Delhi shall have exclusive jurisdiction in all disputes / claim concerning this test and /or results.
- If the results are alarming or unexpected, the patient is advised to contact the laboratory immediately for possible advice.
- Not for medico legal purpose. Opinion based on material made available.

